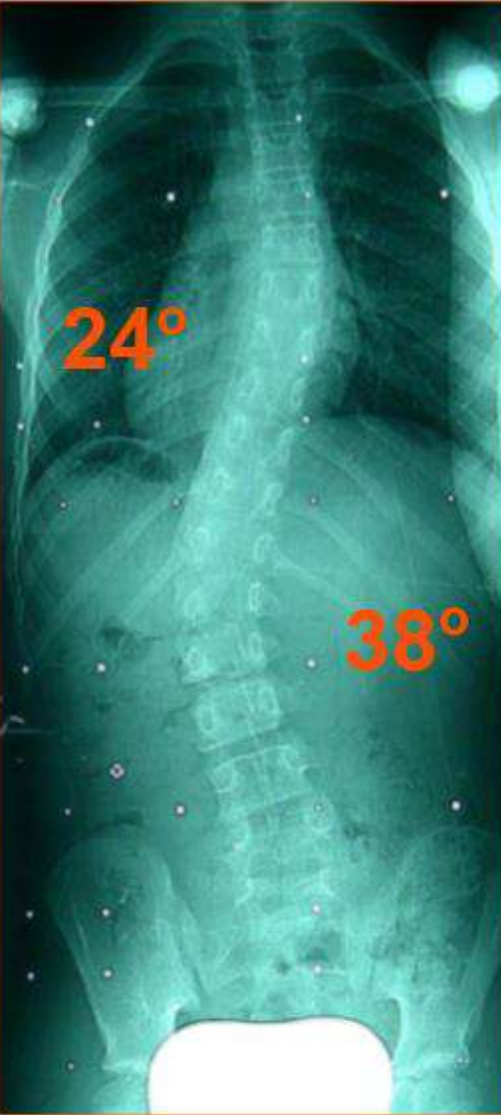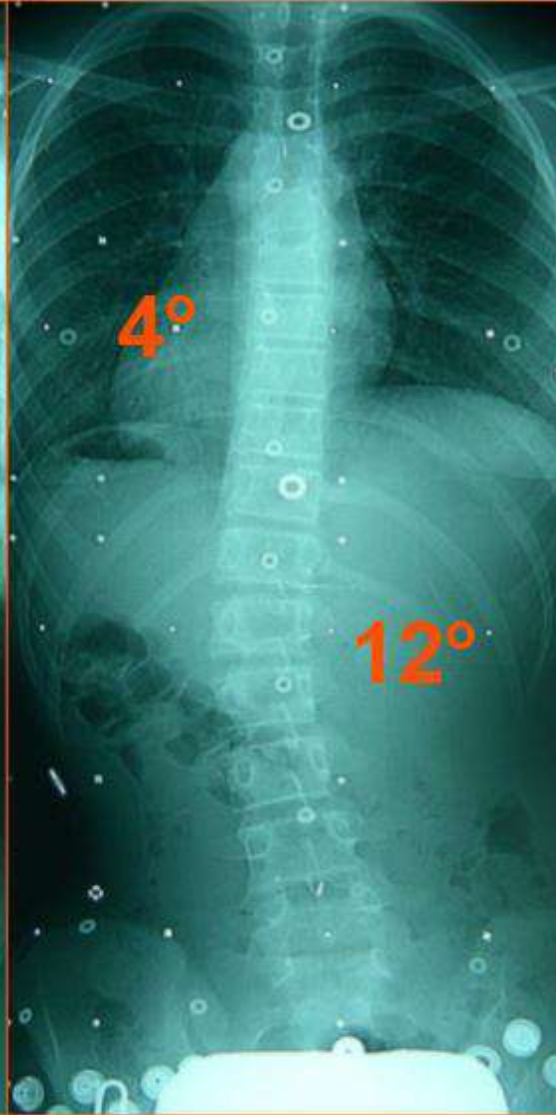


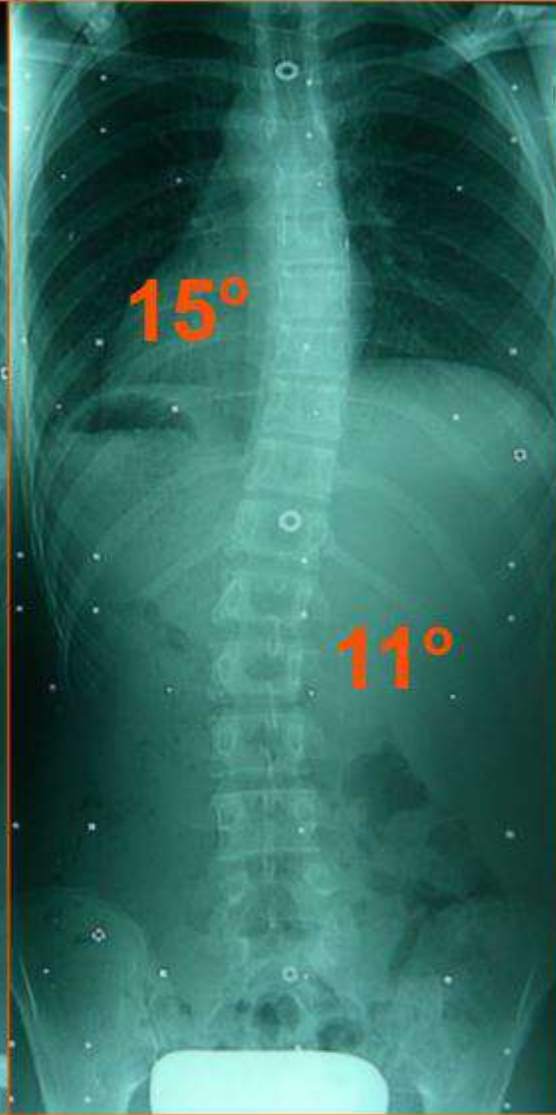10 years 9 months patient (Risser 0)



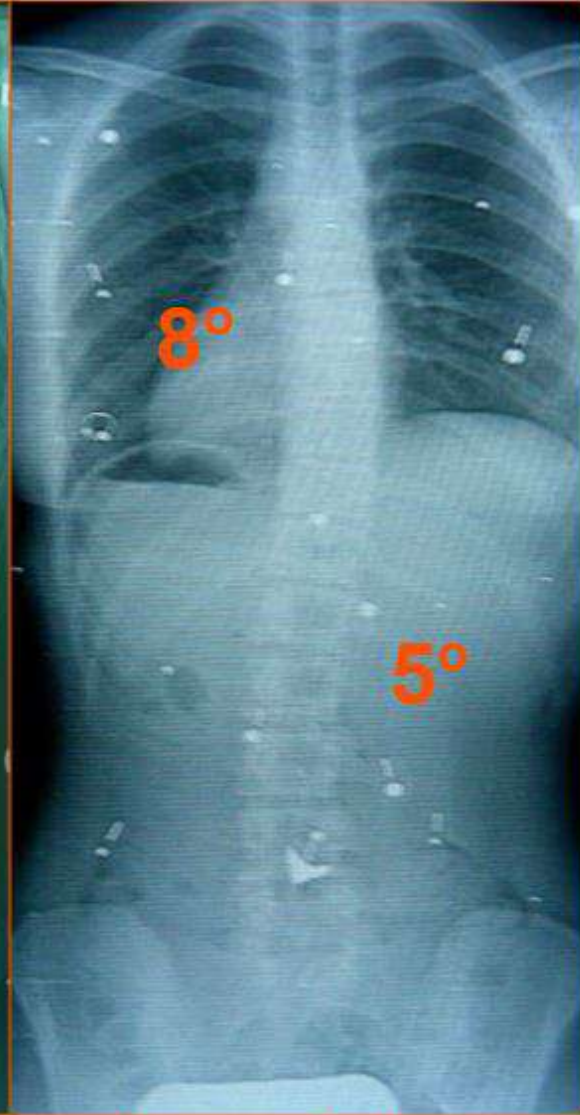Initial WOB x-ray



1st X-ry in brace

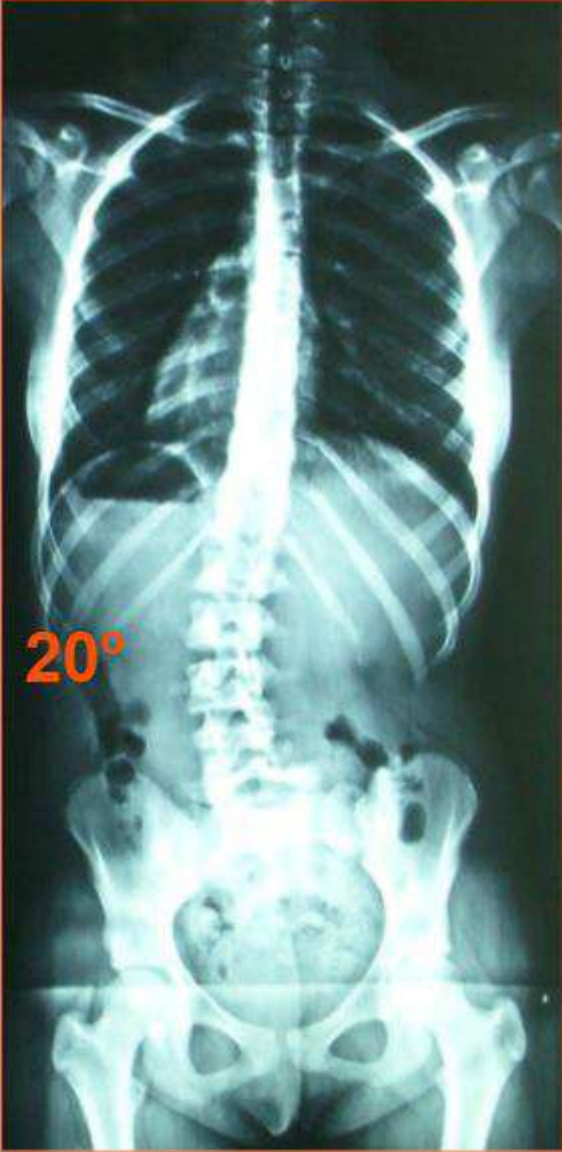

24 months in brace
WOB x-ray

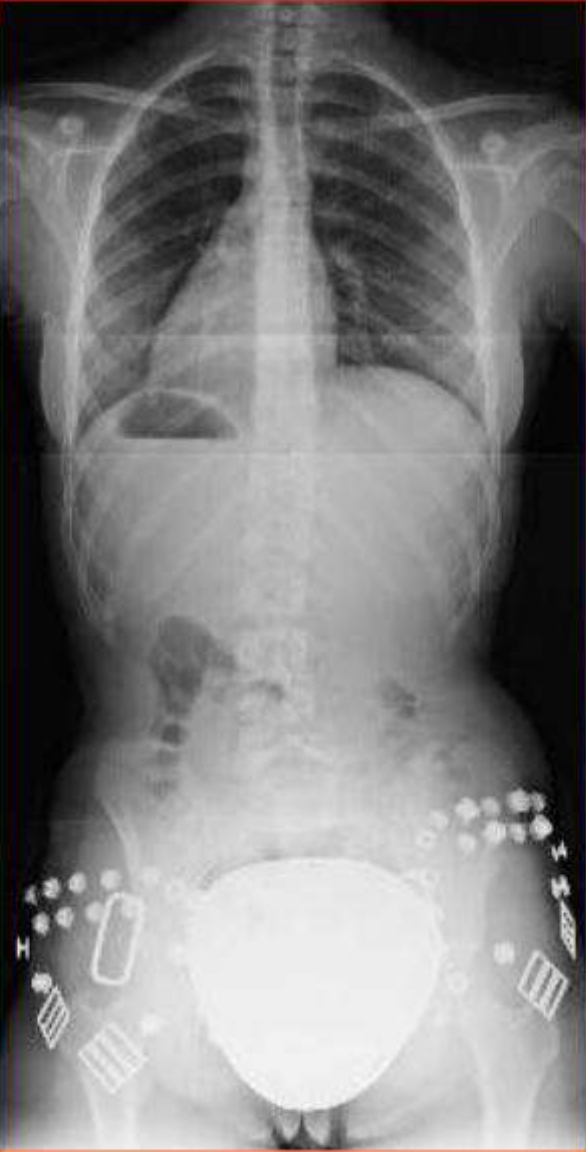

5 years after brace
weaning

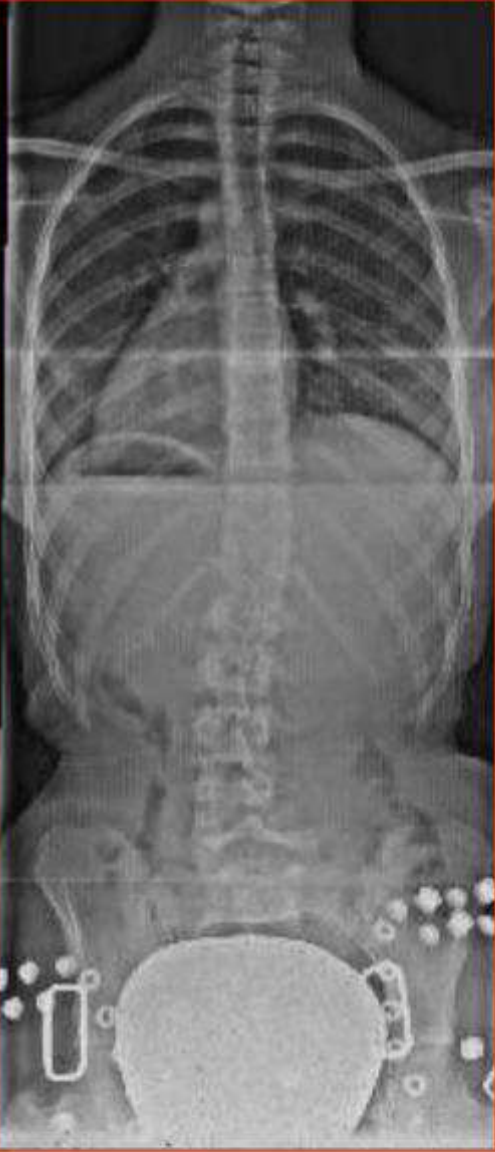Low Back Pain patient (15 years of age)



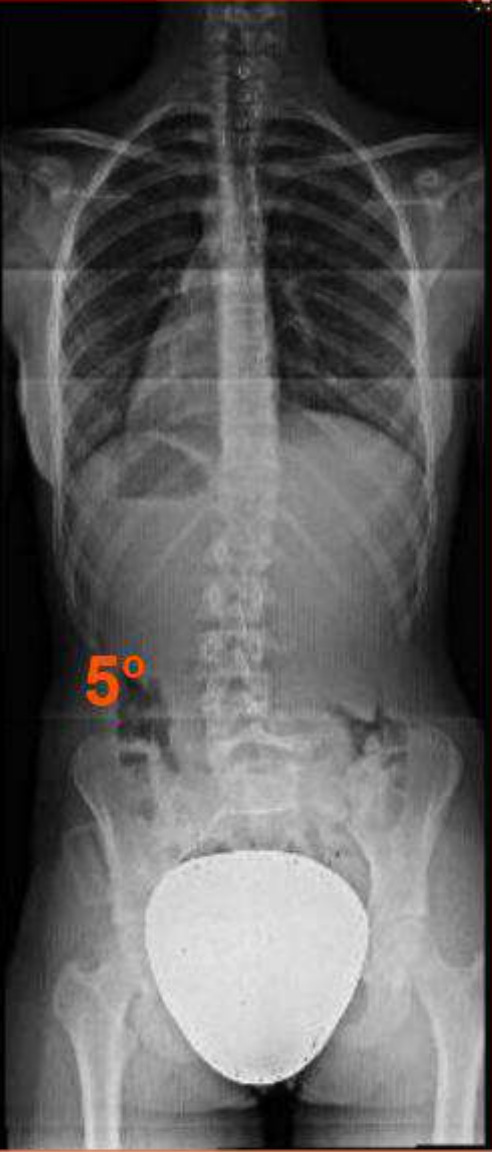Initial WOB X-ray



1 month in brace + shoe lift

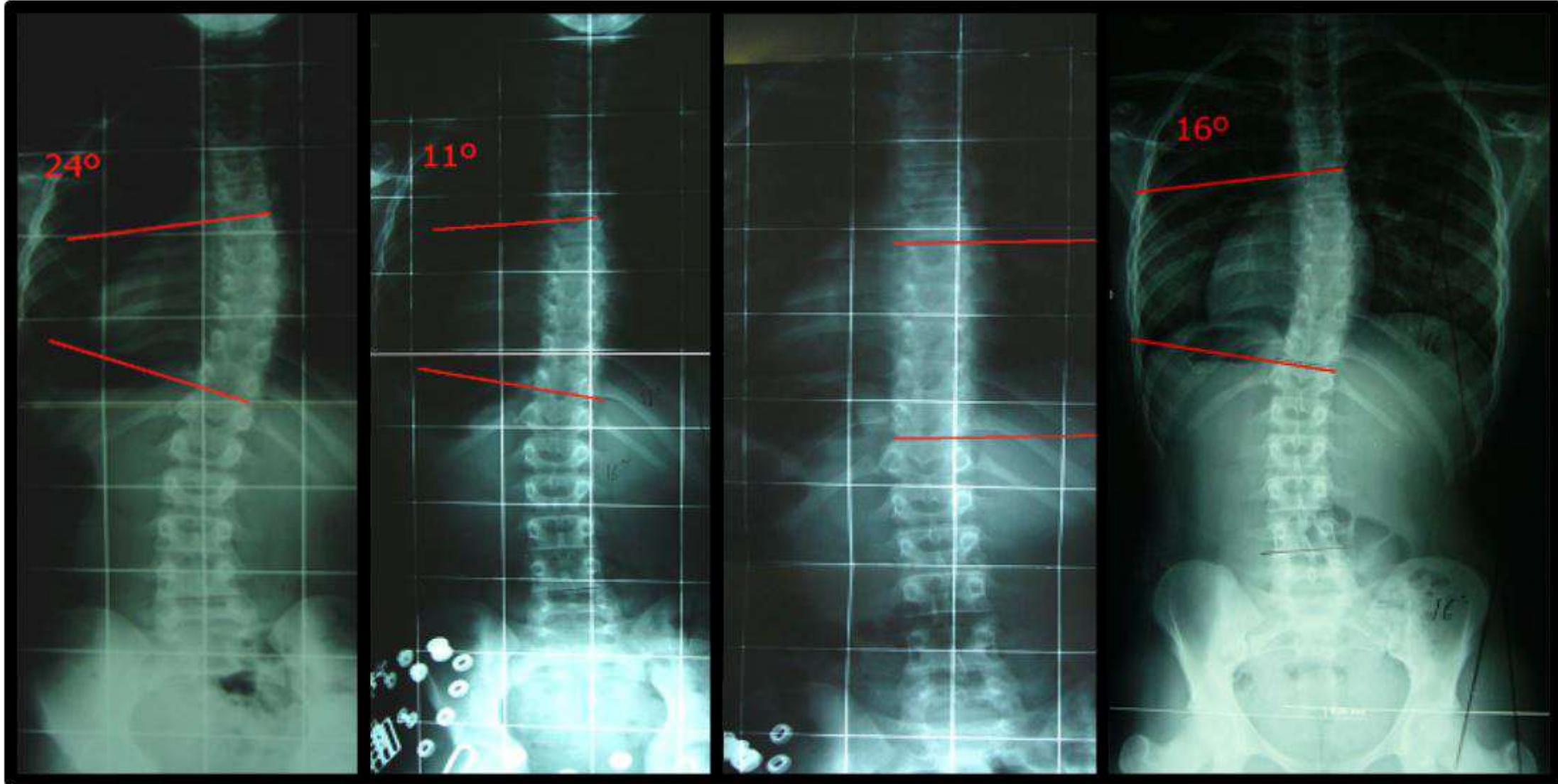


10 months in brace + shoe lift



End of treatment WOB X-ray

Juvenile scoliosis diagnosed at **6 years of age**



Initial WOB X-ray
(11 yoa)

1st WB X-ray

24 months in
brace

End of treatment (15 yoa)
WOB X-ray